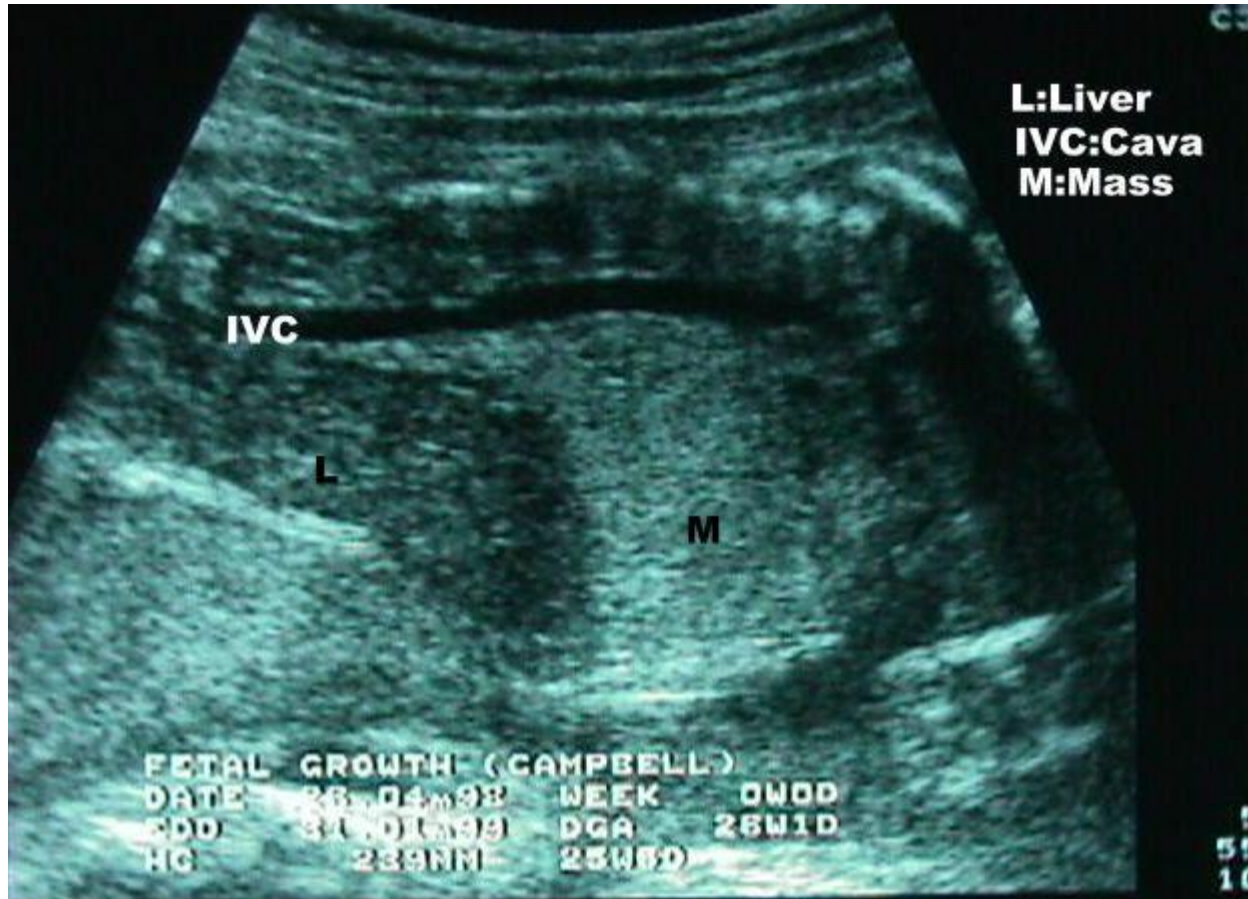
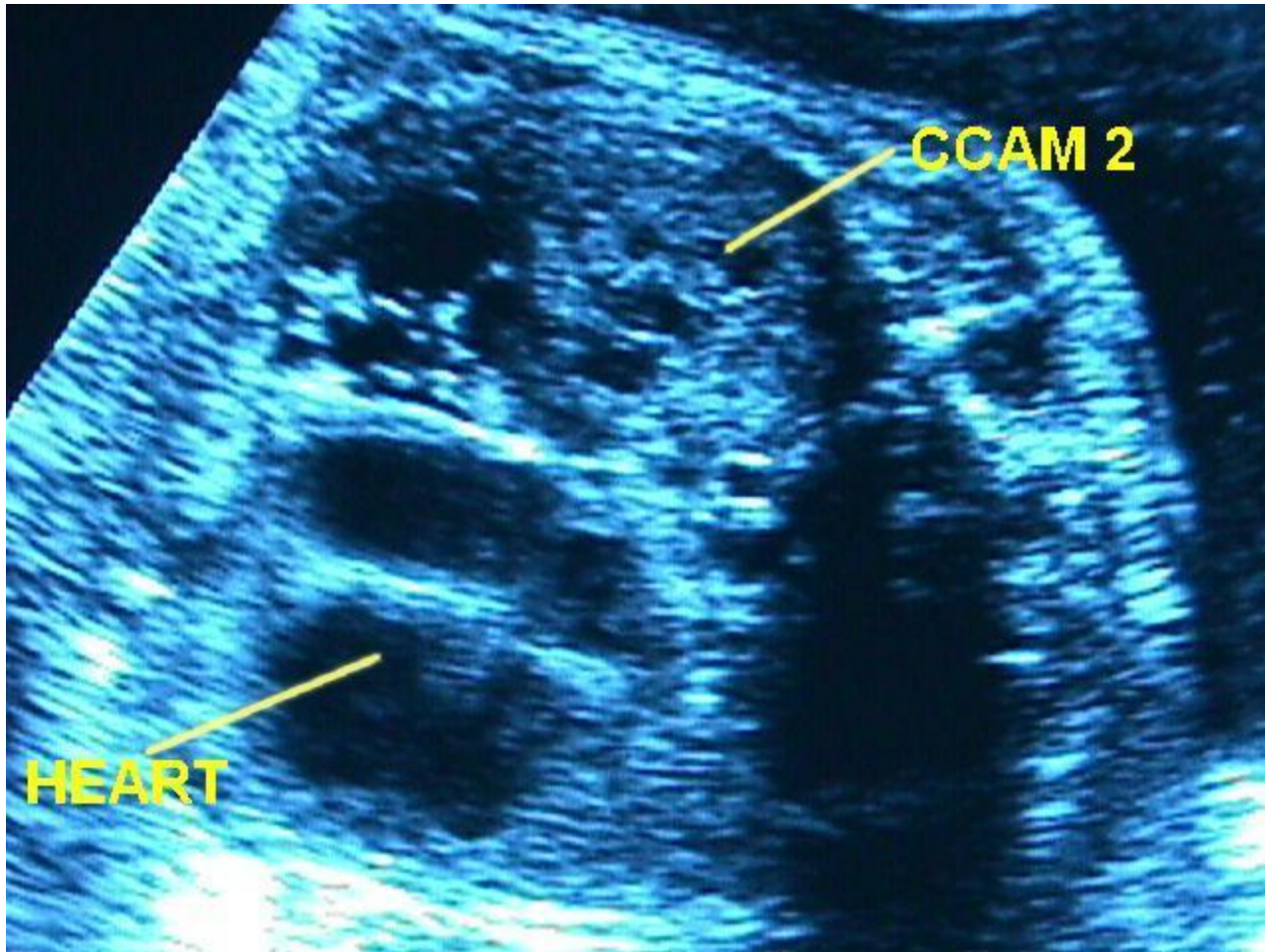


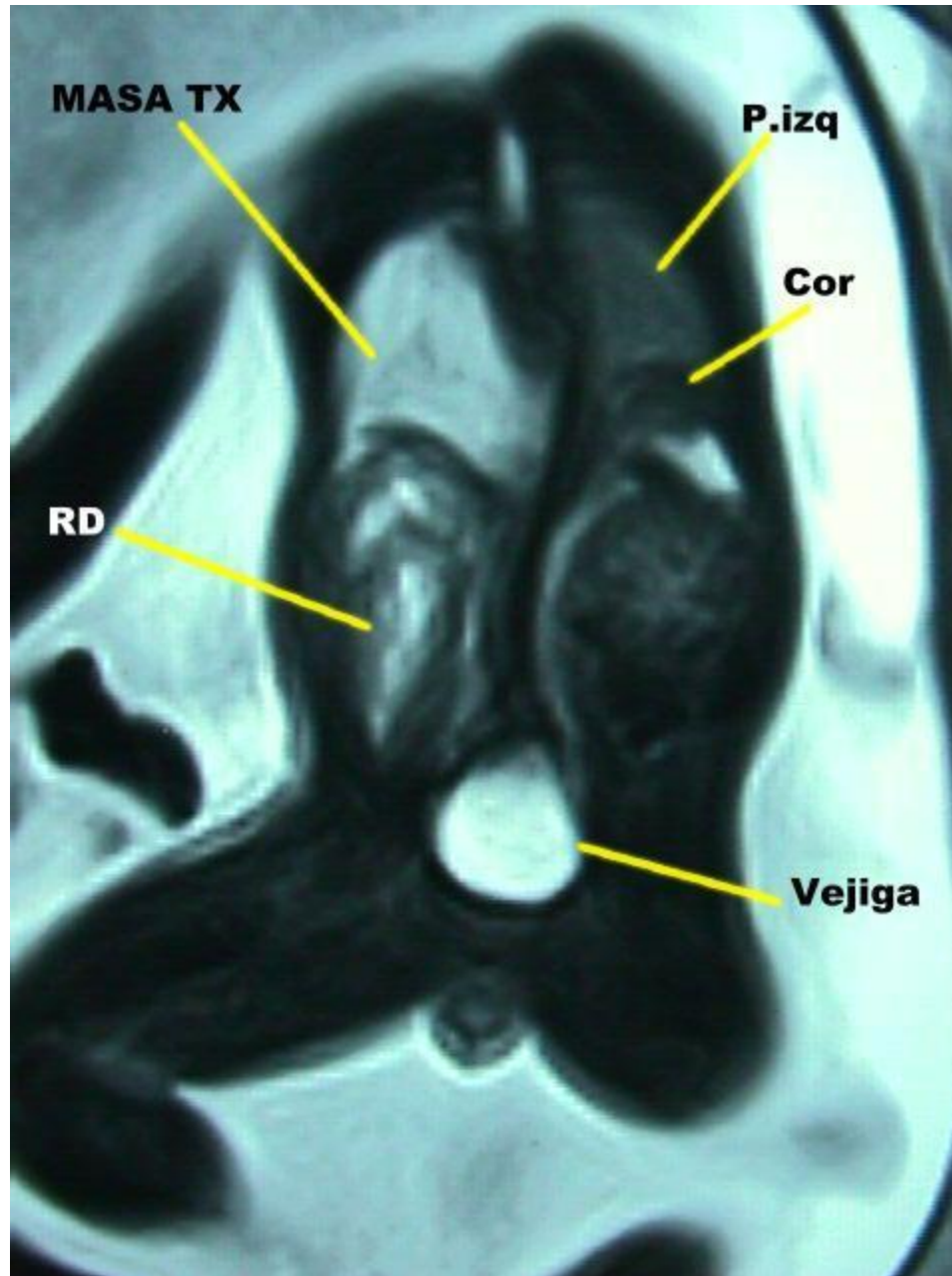
Malformación Adenomatosa Pulmonar Ecografía Fetal



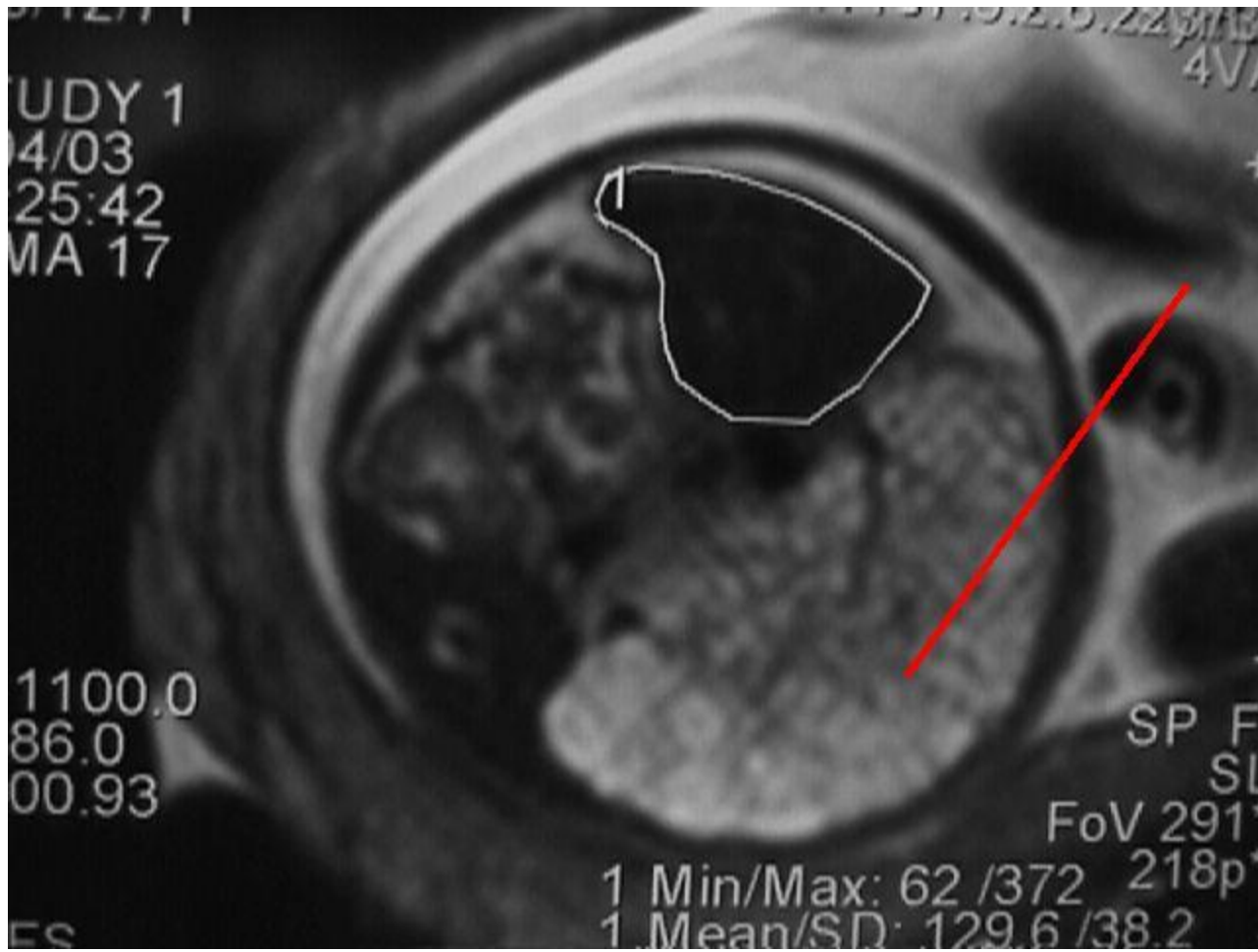
Malformación Adenomatosa Quística Pulmonar



Malformación Adenomatosa Tipo 3



Utsumi 2



Vazquez MAC

